

**PATIENT**

Leo Salmon

**SPECIES**

Feline

**BREED**

DSH

**SEX**

Spayed Female

**AGE**

16 years

**WEIGHT**

6.25 lbs

**INTERPRETED BY**

Beth Johnson, DVM  
DACVIM

**IMAGING PERFORMED BY**

Jenna Walsh, CVT

**HOSPITAL NAME**

Albany AH

**REFERRING VET**

Dr Flanagan

**INVOICE**

12979

**DATE**

5.8.23

**PRESENTING CLINICAL SIGNS**

History: vomiting and losing weight for about two months, was seen at rivers edge 3/22/23  
Bloodwork was wnl, lateral x-ray showed no overt masses, but did have a distended colon filled with stool. No palpable stool on 5/4/23. Cerenia did improve pet's condition while taking it. Current Medications just restarted Cerenia  
Primary Question/Differential to Be Answered in This Exam R/O potential GI lymphoma, vs other possible neoplastic or inflammatory conditions

**ULTRASONOGRAPHIC EXAMINATION OF THE ABDOMEN**

**Urinary System**

Urinary bladder is adequately distended with anechoic contents. No masses, inflammatory changes, echogenic sediment or cystoliths are observed. The urinary bladder, trigone and visible pelvic urethra are normal in thickness with a smooth mucosal surface.

Left kidney is normal in size (3.36 cm), shape and echogenicity. It has smooth peripheral margination. There is a normal 1:3 cortex to medulla ratio with appropriate corticomedullary distinction. There is no evidence of pyelectasia, mineral or infarcts observed.

Right kidney is normal in size (3.67 cm), shape and echogenicity. It has smooth peripheral margination. There is a normal 1:3 cortex to medulla ratio with appropriate corticomedullary distinction. There is no evidence of pyelectasia, mineral or infarcts observed.

**Adrenal Glands**

Adrenal glands are bilaterally uniformly plump egg-shaped adrenals (left: 0.41 cm / right 0.38 cm), hypoechoic in echogenicity with bilateral dystrophic mineralization noted. This is most likely a benign age-related change. This change can be caused by chronic stress/disease, so investigation for/management of other disease (chronic kidney disease, hyperthyroidism, etc.) is recommended.

**Spleen**

Spleen is subjectively normal in size with a normal smooth capsular contour. Parenchyma is appropriately finely textured and homogenous with normal echogenicity relative to surrounding tissue (hyperechoic to liver). No focal nodules or masses are observed. Splenic vasculature appears normal.

**Liver**

Liver is subjectively normal in size with normal smooth curvilinear peripheral contour. Parenchyma is appropriately hypoechoic to the spleen in echogenicity and appropriately mildly coarse and homogenous in echotexture. No focal lesions are observed. Visible vasculature and biliary tree appear normal without distension or congestion.

Gallbladder is non-distended in size. The wall is smooth without visible thickening. Luminal contents are primarily anechoic. There is no evidence of cystic or common bile duct dilation.

**Gastrointestinal**

The visible stomach wall is normal in thickness and layering. The lumen of the stomach is empty with no evidence of obstruction, foreign material or infiltrative disease. Pyloric outflow tract appears patent.

The visible small intestine demonstrates areas of thick muscularis layer relative to mucosa (disruption of the normal 1:3 muscularis:mucosa ratio). Small intestinal submucosa is slightly irregular, thick and hyperechoic, without evident loss of layering appreciated. The lumen of the small intestine is empty with no evidence of obstruction or foreign material.



**PATIENT**

Leo Salmon

The visible colon is normal in wall thickness and layering. Contents are consistent with normal formed feces and gas.

**SPECIES**

Feline

**Pancreas**

The observed pancreas is prominent (enlarged) in size, hypoechoic to surrounding tissue and irregular in shape with a swollen undulating contour. Pancreatic duct dilation is noted. Enhanced hyperechoic ill-defined surrounding fat is noted.

**BREED**

DSH

**Free Abdomen**

A very scant amount of anechoic free fluid is visualized. Lymph nodes are prominent in size with swollen capsular contour. Normal elongated shape (length to width ratio) is maintained. There is no loss of parenchymal detail.

**SEX**

Spayed Female

**ULTRASONOGRAPHIC FINDINGS**

**Findings**

**AGE**

16 years

- Inflammatory bowel disease (IBD) pattern – Thick muscularis has been reported with infiltrative bowel disease including both benign inflammatory disease as well as infiltrative neoplasia such as lymphoma. No aggressive lymphadenopathy, loss of layering, etc. is noted to make lymphoma more probable, but lymphoma cannot be definitively ruled out without tissue sampling.

**WEIGHT**

6.25 lbs

- Chronic active pancreatitis – Mesenteric lymph nodes are prominent in size with swollen capsular contour. Normal elongated shape (length to width ratio) is maintained. There is no loss of parenchymal detail.

**INTERPRETED BY**

Beth Johnson, DVM  
DACVIM

**INTERPRETATION OF THE FINDINGS & FURTHER RECOMMENDATIONS**

A gastrointestinal malabsorption panel (including cobalamin, folate, TLI and PLI) to Texas A&M GI Laboratory is recommended for further evaluation of GI and pancreatic function.

**IMAGING PERFORMED BY**

Jenna Walsh, CVT

Ideally, biopsies of the GI tract, being sure to include ileum if possible, are recommended to definitively diagnose and therefore manage the infiltrative bowel disease.

**HOSPITAL NAME**

Albany AH

If biopsies cannot be obtained, empirical therapies could include diet change, empirical deworming with a 5-day course of Panacur, cobalamin supplementation (unless cobalamin level is evaluated and supplementation is not warranted) and prednisolone (if not contraindicated based on patient contraindications, co-morbidities, etc.). Other supportive therapeutic considerations could include fiber supplementation, especially with large bowel diarrhea and/or a probiotic.

**REFERRING VET**

Dr Flanagan

**INVOICE**

12979

**DATE**

5.8.23



**PATIENT**

Leo Salmon

**SPECIES**

Feline

**BREED**

DSH

**SEX**

Spayed Female

**AGE**

16 years

**WEIGHT**

6.25 lbs

**INTERPRETED BY**

Beth Johnson, DVM  
DACVIM

**IMAGING PERFORMED BY**

Jenna Walsh, CVT

**HOSPITAL NAME**

Albany AH

**REFERRING VET**

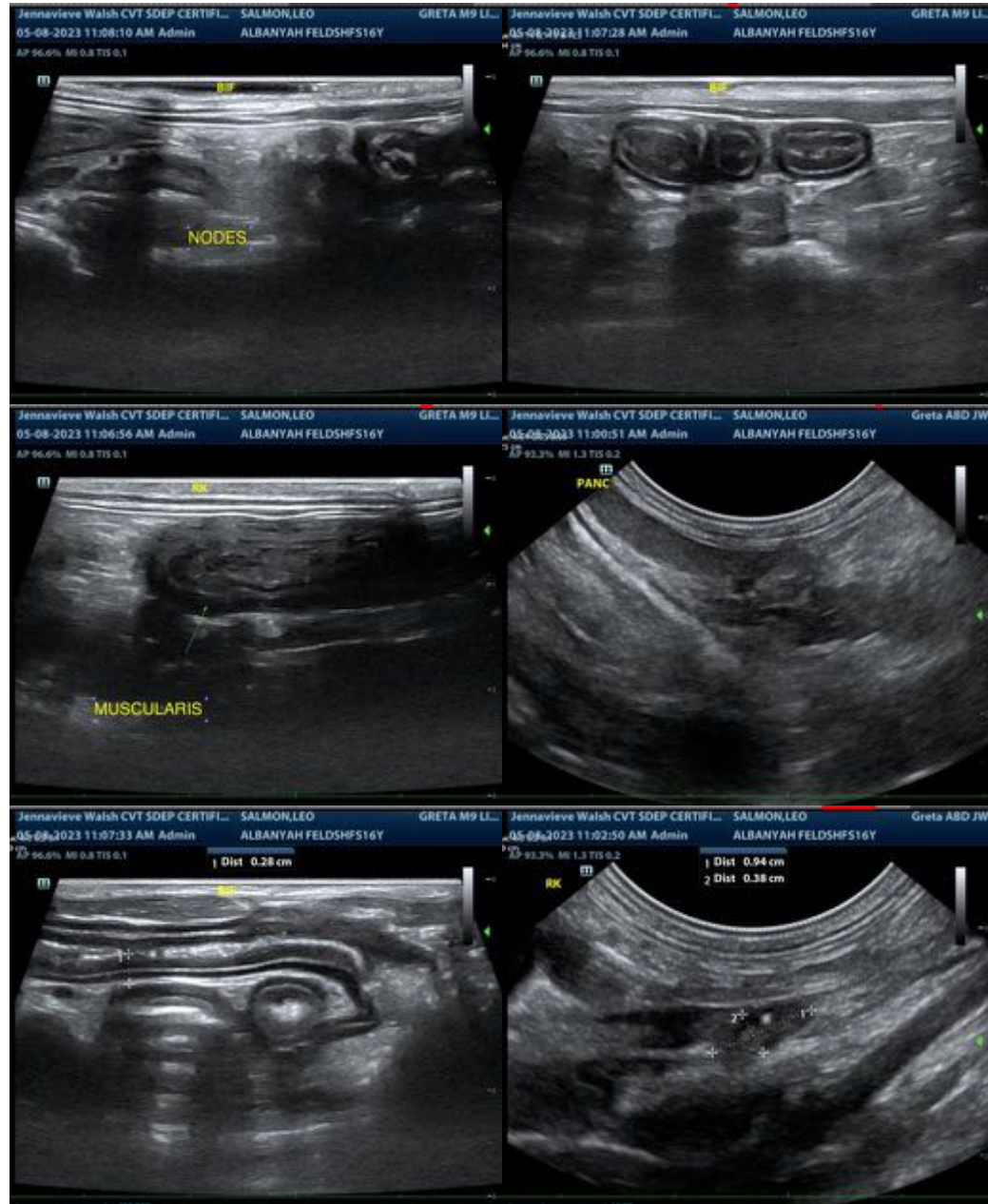
Dr Flanagan

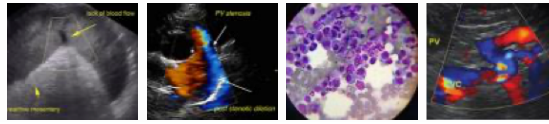
**INVOICE**

12979

**DATE**

5.8.23





**PATIENT**

Leo Salmon

**SPECIES**

Feline

**BREED**

DSH

**SEX**

Spayed Female

**AGE**

16 years

**WEIGHT**

6.25 lbs

**INTERPRETED BY**

Beth Johnson, DVM  
DACVIM

**IMAGING PERFORMED BY**

Jenna Walsh, CVT

**HOSPITAL NAME**

Albany AH

**REFERRING VET**

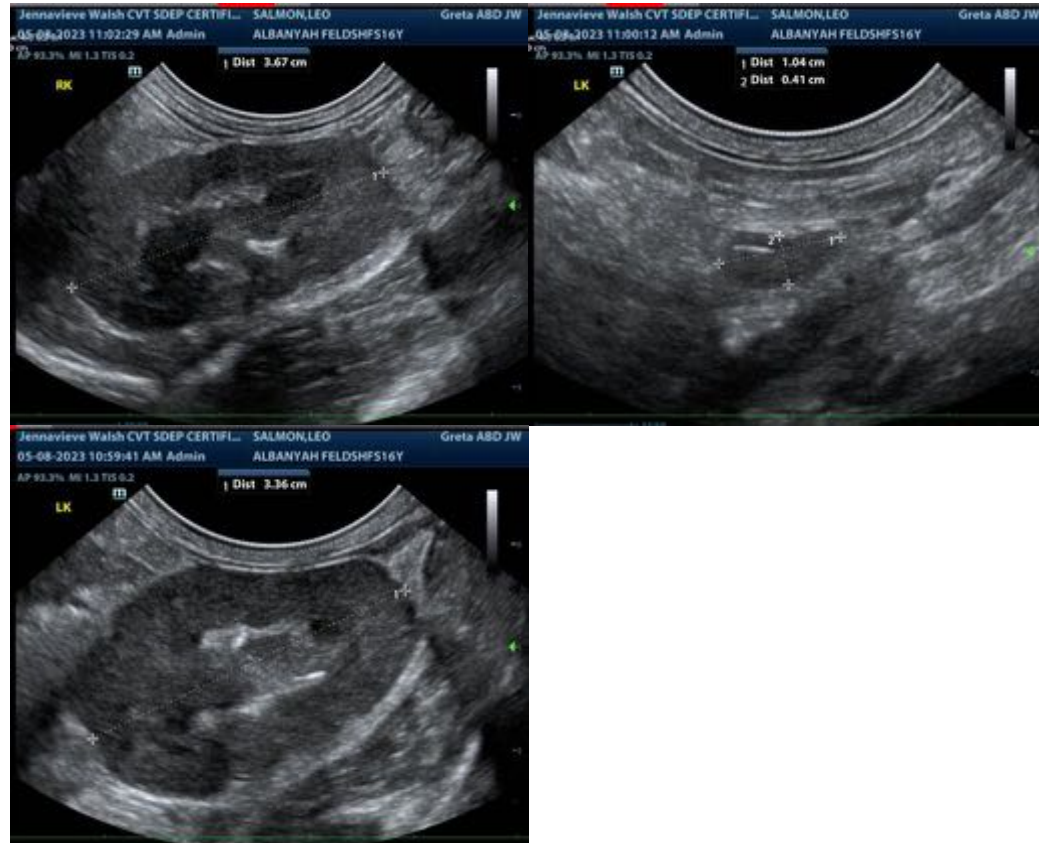
Dr Flanagan

**INVOICE**

12979

**DATE**

5.8.23



The information and recommendations provided are based on the images presented by the referring veterinarian. No evaluation can be communicated regarding pathology that was not visible in the image/video clips provided.

Thank you for this referral. If the clinical or image interpretation does not parallel your findings or if I can be of any further assistance, please contact me.

Beth Johnson, DVM DACVIM  
Beth.Johnson@SonoPath.com